

PennHIP Report

Referring Veterinarian: Dr Susan Seethaler Email: info@indiantrailvet.com	Clinic Name: Indian Trail Animal Hospital WA Clinic Address: 5150 West Barnes Road Spokane, WA 99208 Phone: Fax:
--	--

Patient Information

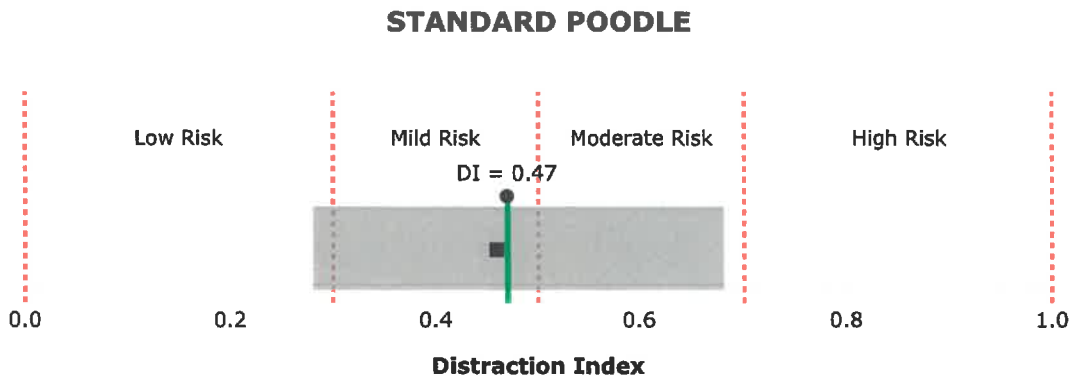
Client: Stephenson, Angie Patient Name: Yukon Reg. Name: EASTERBROOKS AINT NO OTHER MAN PennHIP Num: 196228 Species: Canine Date of Birth: 07 Dec 2022 Sex: Male Date of Study: 30 Nov 2023 Date of Report: 30 Nov 2023	Tattoo Num: Patient ID: 40282 Registration Num: PR26451601 Microchip Num: 933000320556490 Breed: STANDARD POODLE Age: 11 months Weight: 26.5 lbs/12 kgs Date Submitted: 30 Nov 2023
---	--

Findings

Distraction Index (DI): Right DI = 0.47, Left DI = 0.38. Osteoarthritis (OA): No radiographic evidence of OA for either hip. Cavitation/Other Findings: No cavitation present.
--

Interpretation

Distraction Index (DI): The laxity ranking is based on the hip with the greater laxity (larger DI). In this case the DI used is 0.47.
OA Risk Category: The DI is between 0.31 and 0.49. This patient is at mild risk for hip OA.
Distraction Index Chart:



BREED STATISTICS: This interpretation is based on a cross-section of 6419 canine patients of the STANDARD POODLE breed in the AIS PennHIP database. The gray strip represents the central 90% range of DIs (0.28 - 0.68) for the breed. The breed average DI is 0.46 (solid square). The patient DI is the solid circle (0.47).

SUMMARY: The degree of laxity (DI = 0.47) falls within the central 90% range of DIs for the breed. This amount of hip laxity places the hip at a mild risk to develop hip OA. No radiographic evidence of OA for either hip.